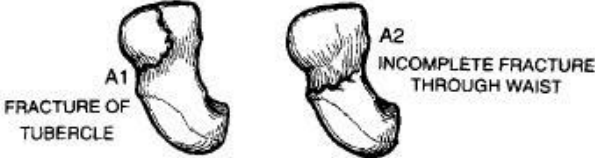
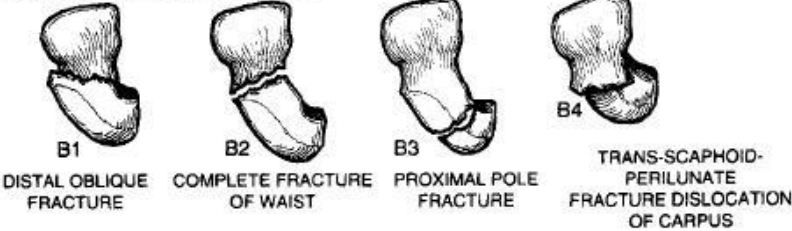


Herbert's klassifikation för indelning av frakturer i os scaphoideum

TYPE A:
STABLE ACUTE FRACTURES



TYPE B:
UNSTABLE ACUTE FRACTURES



TYPE C:
DELAYED UNION



TYPE D:
ESTABLISHED NONUNION

